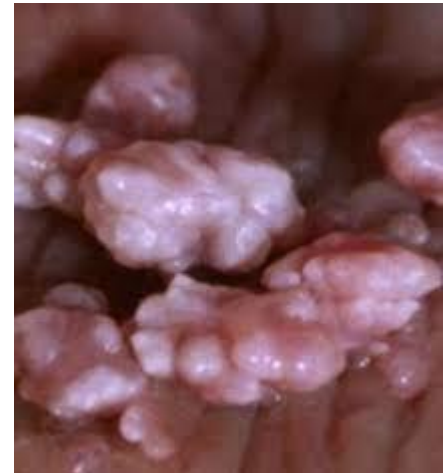

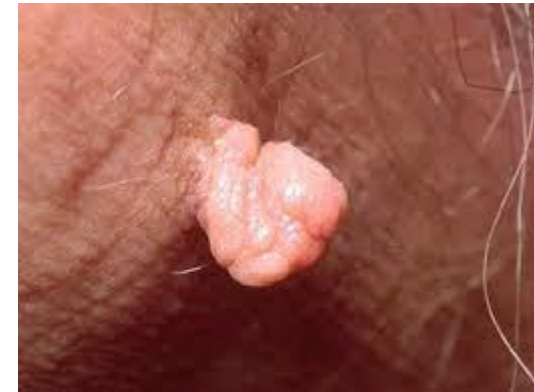INTRODUCTION

- Vulvar and vaginal warts are one of the clinical manifestations of (HPV) infection .
- 90 % of anogenital warts are associated with HPV types 6 and/or 11, low oncogenic potential.



INTRODUCTION

- For most patients, the presence of genital warts is concerning because of:
 1. Their cosmetic appearance
 2. Association with a STD
 3. Bothersome symptoms
 4. Absence of a cure
 5. Social stigma
- Recurrence is common (20 to 30 %)



PRETREATMENT COUNSELING

- Most women want to know **how and when** they acquired the disease.
- We tell them that **HPV is spread by direct physical contact during sex.**
- They may have acquired the infection **years prior to diagnosis** since the **incubation period** can last for months and their first recognition of a lesion may represent a relapse rather than a first episode.

PRETREATMENT COUNSELING

- Therefore, **a new diagnosis of genital warts does not mean that the patient or her partner is having sex outside the relationship.**
- We also inform them that **condoms provide some protection against HPV transmission**, but contact with genital lesions not covered by the condom can result in infection.

Indications for treatment

1. **Alleviation of bothersome symptoms** (pruritus, bleeding, burning, tenderness, vaginal discharge, pain, obstruction of the vagina, dyspareunia) or
2. **Psychologic distress** (main indication)
 - **Warts do not pose serious risks to health or fertility**; therefore, some symptomatic patients may reasonably choose **expectant management** to see if the warts spontaneously resolve.
 - Regression occurred in up to 40 %



Indications for treatment

3. There is no medical indication for treatment of **asymptomatic warts** incidentally noted on physical examination, but **patients should be made aware of the presence of these lesions.**
4. There is no reason to believe that **treating vulvovaginal warts will reduce a woman's future risk of cancer.**

Prolonged treatment with frequent follow-up

- Clearance of warts in 35 - 100 % of patients in 3 -16 w (medical and surgical)but do not necessarily eradicate all HPV infected cells.
- Because clinically and histologically latent HPV can exist beyond the treatment area, **the possibility of clinical recurrence or transmission of HPV to sexual partners.**
- Most HPV infections associated with genital warts in **immune competent patients** are **cleared within 2 years.**

Prolonged treatment with frequent follow-up

- Medical therapies are generally tried first;
- If the patient has not responded to the **initial medical therapy after 3 W** or **complete clearance has not occurred by 6 -12 weeks**, a different medical therapy can be administered .

Prolonged treatment with frequent follow-up

- Surgical therapy
 1. extensive and/or bulky lesions
 2. Those who have **failed to respond adequately to medical therapy.**
- Surgery results in:
 1. High initial clearance rates (90 - 100 %)
 2. *Recurrence rates* are *similar* to those with medical therapy.

Side effects and complications of treatment

- **Localized discomfort** including itching, burning, erosions, and pain since the epithelium is disrupted.
- Complications resulting from treatment include **hypo- or hyperpigmentation, scarring, and, rarely, chronic vulvar pain.**
- **Hypopigmentation** (surgically ablated , imiquimod)
- **Scarring** (surgical procedures that destroy subdermal tissue)



Management of sex partners

- **Sex partners** can **benefit from informational counseling**.
- **Symptomatic partners** can be referred to their health care provider for evaluation and possible treatment.

Management of sex partners

- Given the high prevalence of infection in adults, high frequency of asymptomatic disease, and absence of curative therapy, testing asymptomatic sexual partners for oncogenic strains of HPV is **not recommended** beyond the usual **cervical cancer screening guidelines for women**.
- Screening for other STI is performed according to standard guidelines.

PRETREATMENT EVALUATION

- **Determining HPV type** of the warts is unnecessary.
- The presence of genital warts alone is not an indication for screening for additional STD.
- STD screening is indicated in:
 1. **High risk groups** such as women with new partners or in non-monogamous relationships
 2. **Women ≤ 25 years of age**

Indications for pretreatment biopsy

- Biopsy is not mandatory before initiating therapy, but is recommended when:
 1. **The diagnosis is uncertain**
 2. The lesion has any **suspicious features**, such as fixation (infiltration of dermis), irregular and unusual pigmentation (red, blue, black, brown), induration, bleeding, ulceration, or sudden recent growth.
 3. The patient is **postmenopausal or immunocompromised**.
 4. The lesion is **refractory to medical therapy**

Treatment

- **1) Medical therapy**
- **A :Cytodestructive therapies** :Podophyllotoxin (podofilox) and podophyllum resin (podophyllin):
Both drugs are avoided in pregnancy, TCA and BCA , 5-Fluorouracil
- **B :Immune-mediated therapies** : Imiquimod , Sinecatechins (eg, Veregen) , Interferons , Bacillus Calmette-Guerin
- **2) Surgical therapy** :
- Cryoablation , Laser ablation , Electrocautery , Ultrasonic aspiration , Excision

Medical therapy

- **Patient-Applied:**
 - Podofilox 0.5% solution or gel
 - Imiquimod 5% cream (Aldara)
 - Sinecatechins 15% ointment
 - Topical interferon

Medical therapy

- **Provider-Administered:**
 - Cryotherapy with liquid nitrogen or cryoprobe
 - Podophyllin resin 10-25%
 - Trichloroacetic acid (TCA) or BCA 80%-90%

Medical therapy

- **Key points :**
- Self-administered :Podophyllotoxin (podofilox), imiquimod, sinecatechins, and topical interferon.
- Vaginal warts can only be treated with TCA, BCA, and interferons.
- TCA has no systemic absorption and no known fetal effects(**preferred for pregnant women**).
- If the patient has not responded to the initial therapy after approximately 3 weeks or complete clearance has not occurred by 6 -12 weeks, it is appropriate to switch to a different treatment .

Podophyllotoxin (podofilox)

- Contains the biologically active compound from podophyllum resin.
- Using a **cotton swab**, the patient applies a **0.5 % gel or solution** to external genital warts **twice daily for 3 consecutive days** .
- No more than 0.5 mL of podofilox should be applied in one day.
- She then **withholds treatment for 4 days**, and repeats this cycle **weekly up to 4 times**.

Podophyllum resin

- The clinician applies a **25 % solution** directly to the warts with a cotton swab.
- **No more than 0.5 mL** should be applied during each treatment session and large areas (10 cm² or more) should not be treated in a single application because of potential pain when the area becomes necrotic.
- **The area should air-dry before the patient dresses.**
- **A weaker solution (10 %)** should be used when treating large warts to minimize total systemic absorption, and application to open lesions/wounds should be avoided.

TCA and BCA

- An 80 to 90 % TCA solution is used most commonly, and must be applied by a health care provider.
- It can be used on the **vulva and vagina**, and during **pregnancy**.
- Application of an ointment or gel (such as petroleum or lidocaine jelly) to the normal tissue surrounding the wart can help prevent spreading of acid to unaffected areas.

TCA and BCA

- If excess TCA is applied, it can be *neutralized* by washing with soap *or sodium bicarbonate* solution.
- The patient should not sit, stand or dress until the treatment area has dried.
- **Repeated weekly application is required for 4-6 weeks**, or until the lesions have cleared.
- **70 % clearance rate.**

Fluorouracil (FU)

- *FDA has not approved* any formulation of FU for treatment of **anogenital warts**
- *Contraindicated in pregnancy*
- A disadvantage of topical FU is that it is often poorly tolerated because of burning, pain, inflammation, edema, or painful ulcerations
- Several dosing protocols have been suggested, ranging from *twice daily application to once weekly for several weeks.*
- Zinc oxide cream or petroleum jelly can be applied to unaffected areas.

Immune-mediated therapies

- Both *imiquimod* *and interferon* initiate a local immune response at the site of the wart that ultimately may clear the lesions.
- *Imiquimod and topical interferon* may be self-administered; **injectable interferon** is given in the office.
- Experience with these agents is more limited than for other medical therapies.

Imiquimod

- Hand washing before and after cream application is recommended.
- **Aldara (5 % imiquimod) is applied 3 days per week for up to 16 weeks**
- **Zyclara (3.75 % imiquimod) is applied daily for up to 8 weeks.**
- **complete clearance :40 -50 %**
- up to 30 % will experience a recurrence within 12 weeks.
- A tube of Aldara 5 percent or Zyclara 3.75 percent costs in the range of USD \$800 to \$900.

(Sinecatechins) Veregen

- Is a botanical drug product for self-administered topical treatment of external anogenital warts.
- *A 0.5 cm strand of ointment* is placed on each wart and a finger is used to cover the wart with a thin layer of the ointment 3 times each day for up to 16 weeks.
- It should not be used in the **vagina** or **anus**, **immunocompromised women** and **women with active genital herpes lesions** because safety and efficacy have not been established.

Interferons

- A systemic therapy (IM&SQ injection) and topically
- Intralesional injection of 0.5 to 1.5 mu is administered **2-3 times per week for up to 9 weeks.**
- Local anesthesia is recommended.
- Interferon may be used as adjunctive therapy to surgical and cyto-destructive treatments, especially in patients with refractory lesions.
- **Interferons are contraindicated in pregnancy.**

(BCG) Bacillus Calmette-Guerin

- Topical administration
- It has been used primarily for treatment of *perianal warts in men* and requires further study.

Surgical therapy

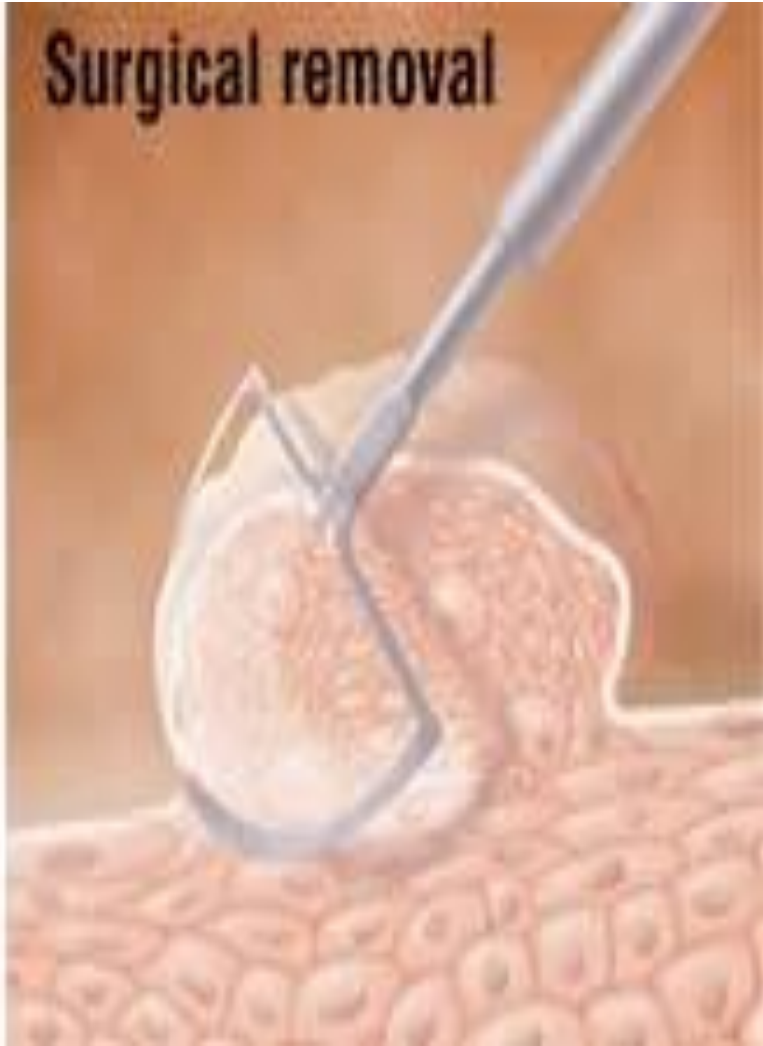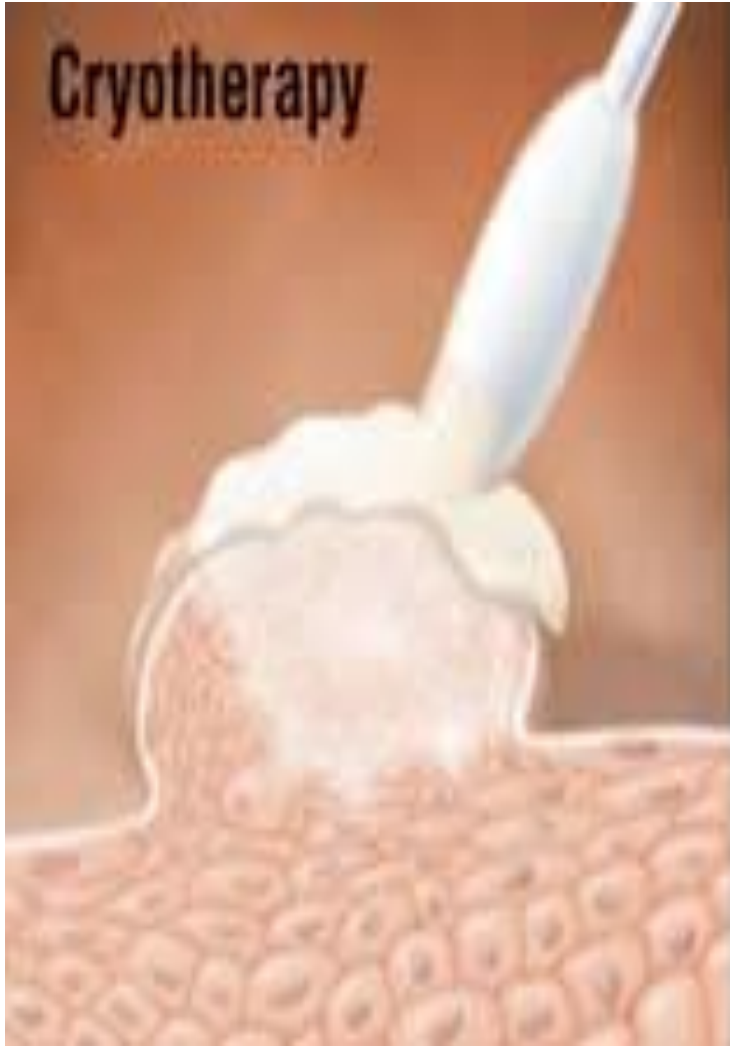
- Consist of **ablative** and **excisional procedures**.
- In patients with **extensive or multifocal disease**.
- **Advantage** :1- fewer visits for treatment 2-repeated procedures are sometimes necessary, especially with cryotherapy.
- **Disadvantage** of ablative therapies:
 - 1- Persistent hypo- or hyperpigmentation is not uncommon.
 - 2-Require anesthesia & operating room
 - 3-Scarring, especially when the subdermal layer is destroyed.

Cryoablation

- Liquid nitrogen (cotton-tip applicator or spray)
Nitrous oxide (cryoprobes)
- **Vulvar lesion**
- **30 - 60 seconds** Until the **ice ball 2 mm** from the edge of the wart
- **Repeated weekly** application is required **until the lesions have resolved.**
- **Not recommended for use in the vagina** because of the risk of *vaginal perforation* and *fistula formation*
Liquid nitrogen
- ***Post-treatment hypopigmentation*** is also relatively common.

Laser ablation

- CO2 laser
- Indications:
 1. Extensive or multifocal lesions
 2. Vaginal warts
- **Advantage: Maintains normal vulvar anatomy**(up to 28 % of patients develop some scar formation post-laser surgery) .
- **Disadvantage: *Pain and hypopigmentation ,chronic pain and vulvodynia*** .
- For patients with multifocal or refractory disease, a combination of techniques is often effective.



Electrocautery

- Used for ablation of *vulvar or vaginal lesions*
- Advantage of this approach over cryoablation is that a **single treatment session** is usually adequate for eliminating the warts.
- Disadvantage is that electrocautery requires administration of **anesthesia and use of an operating room**.
- If available, **laser ablation is generally preferable to electrocautery** because it is associated with *less bleeding* and *discomfort* following the procedure.

Ultrasonic aspiration

- The Cavitron ultrasonic aspirator (CUSA) technique utilizes ultrasound to fragment and aspirate warty tissue .
- *This allows removal of epithelium without damage to underlying tissue.*

Excision

- Histological diagnosis
- Typically, exophytic lesions are tangentially excised or shaved to the level of normal skin using scissors or a surgical knife, and **then the base of the lesion is cauterized** .
- For larger lesions, wide local excision is often required.
- **Adverse sequelae** : include pain, dyspareunia, scar formation, and infection.

Nonpregnant immunocompetent women

- In general, if the patient has not responded to the; **initial therapy after approximately 3 weeks** or **complete clearance has not occurred by 6 to 12 weeks**, it is appropriate to switch to a different treatment.

Self-administered therapy

- We suggest imiquimod or podophyllotoxin (podofilox) for **initial therapy** of women with a small area of external genital warts (eg, ≤ 5 small warts), as long as the patient can comply with home therapy.
- **Prefer imiquimod** because of its immune stimulation and demonstrated effectiveness against dysplasia (in case there is any unrecognized dysplasia in the lesion),
- but its **higher cost is a disadvantage.**

Office based therapy

- We suggest **TCA or cryotherapy** for initial office-based treatment of women who cannot comply with self-administered therapy or as a **second-line approach** for those who *fail home therapy*.
- For patients who **fail monotherapy or cryotherapy**, we suggest using **TCA + imiquimod** .
- Because of the side effects associated with cryoablation, we prefer medical therapy.

Limited vaginal disease

- We suggest **TCA** for treatment of a small area of **vaginal warts** (eg, ≤ 5 small warts).
- TCA, BCA, and interferons are the only medications that can be used to treat vaginal warts.
- **Laser ablation** is our preferred surgical approach as it is possible to reach into the vagina and the depth of treatment can be controlled.

Extensive and/or bulky lesions

- For patients with extensive ($>20 \text{ cm}^2$) and/or bulky disease
- we suggest surgery as initial therapy because medical therapy alone often requires a *prolonged course* of treatment and is often inadequate and *poorly tolerated*.
- Laser ablation is less destructive and less technically challenging than excision, and better tolerated than electrocautery.

Recurrent & Refractory disease

- For patients with **recurrent disease**, **the same treatment that resulted in initial clearance of warts** may be used again and is likely to be successful.
- For **refractory disease**, we suggest a **surgical approach** or a **combination of intralesional interferon and TCA**.
- An **excisional procedure or biopsy** should be performed to exclude **intraepithelial neoplasia** or **cancer** by histopathological examination.

Postmenopausal women

- Postmenopausal women who present with warty-appearing lesions **should be biopsied** before initiation of therapy, as these women have a **greater chance of having an underlying vulvar intraepithelial neoplasia or vulvar cancer than younger women.**

Pregnant women

- TCA has no systemic absorption and no known fetal effects; therefore, it is the preferred medical treatment for pregnant women.
- Cryoablation is also considered a safe and effective treatment for use in pregnancy .
- laser ablation in pregnancy for bulky, potentially obstructive lesions, with success rates of 90 to 100 % .
- **The risk of wart recurrence appears lowest when the treatment is delayed until the third trimester.**

Vertical transmission and mode of delivery

- HPV can manifest in young children as **mucosal, conjunctival, or laryngeal disease**. **Juvenile-onset respiratory papillomatosis** (JRP) is the most severe outcome, although rare.
- as well as the potential morbidity of cesarean delivery, and the fact that elective cesarean delivery has not been proven to prevent transmission of HPV, we suggest not performing cesarean delivery for women with anogenital warts for the sole indication of preventing JRP or vertical transmission .
- **Cesarean delivery is indicated** if :
- **vulvar or vaginal warts obstruct the birth canal**, as the lesions may avulse and hemorrhage or cause dystocia during an attempted vaginal delivery.

HIV infected and immunocompromised women

- *Vulvar biopsy* is indicated when warts are identified in immunocompromised women because *high-grade intraepithelial neoplasia* is more common in warty lesions in these patients .
- In fact, high-oncogenic risk HPV types are detected in up to 50 % of genital warts removed from immunocompromised .
- we suggest that immunocompromised women initially self-treat their warts with imiquimod.(Topical 5 %)
- We *prefer surgical excision to laser therapy*, as the former allows pathologic analysis of removed tissue.



Involvement of the clitoris

- We treat warts on the clitoris with the **same therapies used on vulva warts.**
- Surgical procedures on the clitoris should be performed by physicians with experience operating in this sensitive area.

POSTTREATMENT ISSUES

- Supportive care :
 1. Use of sitz baths
 2. Mild analgesics (eg, acetaminophen)
 3. Loose clothing can relieve discomfort and aid healing.
- Postoperative pericare is important for **prevention of wound infection and breakdown.**

POSTTREATMENT ISSUES

- Sexual activity :
- Sexual activity may be resumed when the patient feels comfortable and after any operative sites have healed, but this may take several weeks.
- Cancer screening :
- Women with anogenital warts should undergo cervical cancer screening according to standard guidelines.

POSTTREATMENT ISSUES

- Follow-up :
- There are no standards for surveillance following treatment for genital warts.
- Follow-up appointments at least monthly are important for assessing the response to therapy and managing complications .
- Most patients who develop **recurrent or refractory** disease are diagnosed within 3- 6 months of therapy.

POSTTREATMENT ISSUES

- New oral, vulvar, or vaginal warts should be evaluated by a medical professional.
- Women with perianal warts or a history of receptive anal intercourse may be at **increased risk of high-grade anal squamous intraepithelial neoplasia**, but there is insufficient evidence to recommend screening anal cytology .

SUMMARY

- The main indications for treatment of vulvovaginal warts are:
 1. Bothersome symptoms
 2. Psychologic distress
- Patients should be advised that up to:
- **40% of vulvovaginal warts will resolve without treatment.**

SUMMARY

- The majority of genital warts are cleared by a course of medical therapy.
- **No treatment is significantly superior to another or appropriate for all patients and all types of warts.**
- If the patient has not responded to the initial therapy after **3 weeks or complete clearance has not occurred by 6 to 12 weeks**, it is appropriate to switch to a different method.

SUMMARY

- **Biopsy to exclude precancerous or cancerous lesions** is not necessary routinely, but is indicated when warts are identified in:
 1. **Immunocompromised**
 2. **Postmenopausal women, when the lesions are visually atypical**
 3. **When warts fail to respond to standard therapy.**

SUMMARY

- For **nonpregnant women with limited vulvar disease** who can comply with self-therapy at home, we suggest **imiquimod over podophyllotoxin** as initial medical treatment.
- **Sinecatechins** are a reasonable alternative.
- For **nonpregnant women with limited vulvar disease** who cannot comply with self-therapy or *fail self-therapy*, we suggest treatment with ***TCA rather than cryotherapy***.

SUMMARY

- For nonpregnant women with limited vulvar disease that does *not clear with monotherapy*, we suggest treatment with imiquimod + TCA.
- For nonpregnant women with limited vaginal disease, we suggest TCA for initial medical therapy.
- Laser ablation is our preferred surgical approach as it is possible to reach into the vagina and the depth of treatment can be controlled.

SUMMARY

- For pregnant women with bothersome symptoms from vulvar or vaginal warts, we suggest treatment with *TCA rather than cryoablation*.
- For treatment of potentially obstructive lesions, we suggest laser therapy rather than excision.
- These therapies have no known fetal effects.

SUMMARY

- For patients with *extensive* ($>20\text{ cm}^2$) *and/or bulky* disease, we suggest *surgery* as initial therapy.
- **Laser ablation** is less destructive and *less technically challenging than excision*, and **better tolerated than electrocautery**.

SUMMARY

- For patients with recurrent disease, *the same treatment that resulted in initial clearance of warts* is repeated and is likely to be successful.
- For refractory disease, we suggest a surgical approach or a *combination of interferon and TCA*.
- For *immunocompromised women without extensive and/or bulky lesions*, we suggest self-treatment with imiquimod as first-line therapy .

Questions?

